牛肉肌肉背侧面图解

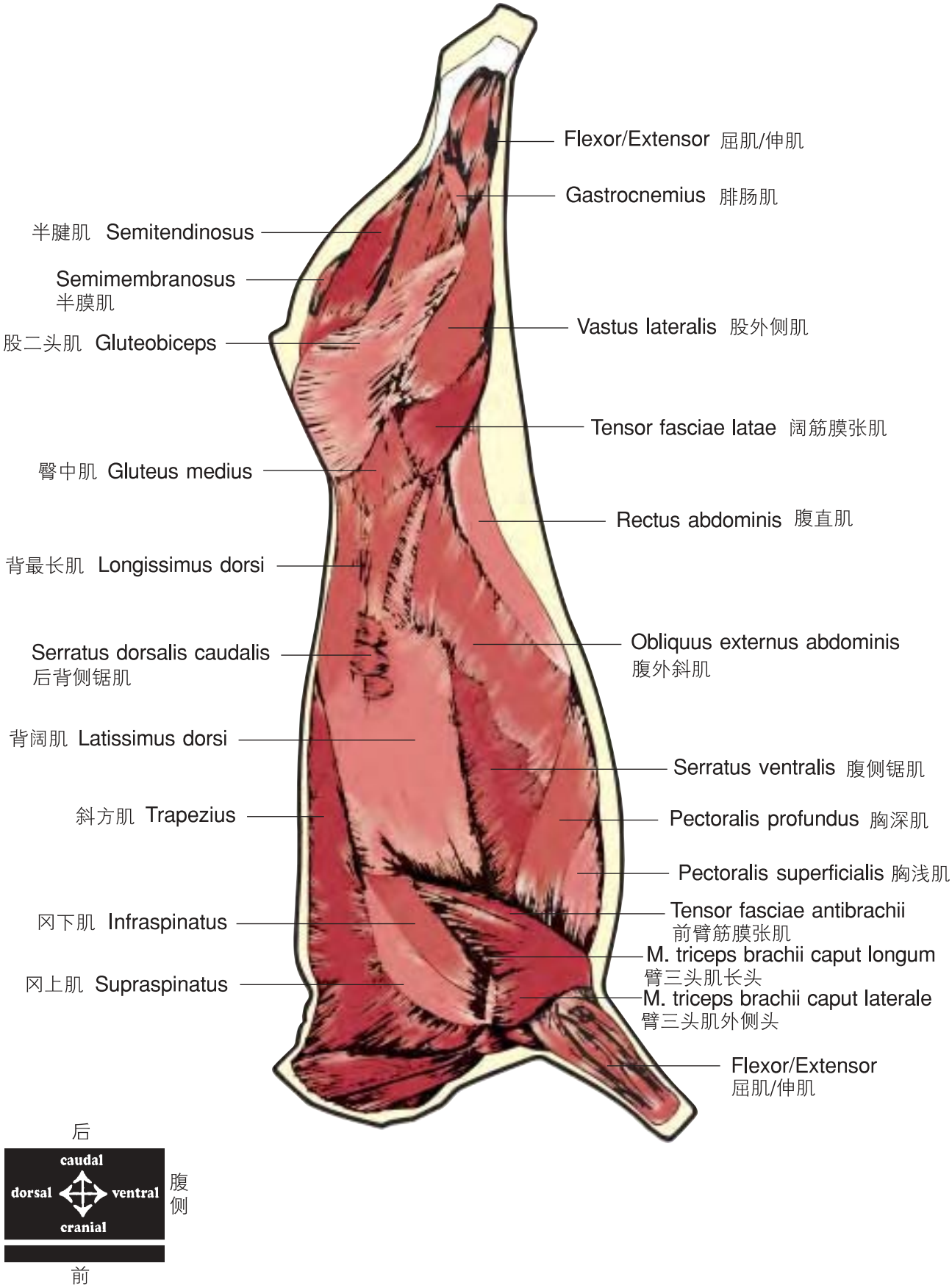
Flexor/Extensor 屈肌/伸肌
Gastrocnemius 腓肠肌
半腱肌 Semitendinosus
Semimembranosus
半膜肌
Vastus lateralis 股外侧肌
股二头肌 Gluteobiceps
Tensor fasciae latae 阔筋膜张肌
臀中肌 Gluteus medius
Rectus abdominis 腹直肌
背最长肌 Longissimus dorsi
Obliquus externus abdominis
腹外斜肌
Serratus dorsalis caudalis
后背侧锯肌
背阔肌 Latissimus dorsi
Serratus ventralis 腹侧锯肌
斜方肌 Trapezius
Pectoralis profundus 胸深肌
Pectoralis superficialis 胸浅肌
Tensor fasciae antibrachii
前臂筋膜张肌
冈下肌 Infraspinatus
M. triceps brachii caput longum
臂三头肌长头
冈上肌 Supraspinatus
M. triceps brachii caput laterale
臂三头肌外侧头
Flexor/Extensor
屈肌/伸肌
后
caudal
背侧
dorsal
ventral
腹侧
cranial
前